



Contents lists available at ScienceDirect

International Journal of Pediatric Otorhinolaryngology

journal homepage: www.elsevier.com/locate/ijporl

Case Report

Familial lower lip facial paralysis with asymmetric smile: Selective neurectomy of the cervical branch

Tristan Klosterman^{a,c,*}, Sedat Ulkatan^b, Thomas Romo III^a, Teresa O.^a^a Facial Nerve Center, Lenox Hill and Manhattan Eye, Ear and Throat Hospitals, 210 East 64th Street, 7th Floor, New York, NY 10065, United States^b Roosevelt Hospital, 1000 10th Avenue, New York, NY 10019, United States^c Highland Hospital, 1411 E 31st St, Oakland, CA 94602, United States

ARTICLE INFO

Keywords:

Facial nerve
Paralysis
Congenital
Cervical branch
Selective neurectomy
Facial nerve monitoring

1. Introduction

Facial nerve paralysis in children is relatively rare and stems from a wide variety of entities. Congenital, acquired, iatrogenic, idiopathic etiologies all play a role, with Bell's palsy remaining the most common cause [1]. While there is significant literature on the most prevalent causes, familial facial nerve paralysis has only been sporadically described [1]. Prior studies have noted association with multiple facial nerve branches, specific alleles 3q21-22 and autosomal dominant transmission [2]. Congenital muscle hypoplasia resulting in asymmetric smiles have also been described, specifically of the depressor anguli oris [3]. While syndromic causes such as Mobius or Melkersson-Rosenthal syndromes are relatively well known, true hereditary causes are rare and poorly understood. To highlight the difficulty with the diagnosis and treatment of these cases, presented are two sisters with isolated familial unilateral cervical branch palsy. This defect has not been reported and frustratingly mimics marginal mandibular weakness. Careful evaluation with intraoperative facial nerve monitoring was used to identify the aberrant nerve branches and allow for selective neurectomy [4].

2. Report of two cases

Two sisters, 8 and 14 years old, presented with isolated right lower lip weakness and asymmetric smile. Both patients had no history of developmental abnormalities nor facial symmetry at rest. Their family

history was noncontributory and both children were the product of full term spontaneous atraumatic births. The parents had decided to wait until the children themselves voiced an interest in having an intervention. When they sought intervention, there were difficulties in accessing care in their home state. A thorough discussion was conducted with the parents and patients regarding the various non-surgical and surgical options. Given the significant loss of depression of the right hemi-lip, the etiology was thought to be dysfunction of the depressor anguli oris due to muscular hypoplasia or marginal mandibular nerve palsy. Contralateral chemodenervation with Botox[®] (onabotulinumtoxin A) of the lower lip depressors was declined due to the patient's inability to tolerate multiple awake injections and their desire for a single definitive procedure. Individual muscle sacrifice was also declined due to unpredictable results. Ultimately, the decision was made with the family to improve symmetry with contralateral selective neurectomy. We hypothesized that the marginal mandibular branch would be sacrificed. Genetic testing was additionally offered but declined by the family. Institutional review board approval was granted for this project. The patients presented for exam under anesthesia, facial nerve monitoring, and selective contralateral neurectomy. Facial nerve monitoring (CMAP - continuous monitoring of the action potential) was performed which allowed for preoperative mapping with identification of branch topography and action potentials by a specialized neurophysiologist [4]. In brief, needle probes were placed in the midline mentalis, orbicularis oris and nasalis and attached to a neuromonitor. As a stimulator probe was placed on the facial skin, the monitor would

* Corresponding author. Facial Nerve Center, Lenox Hill and Manhattan Eye, Ear and Throat Hospitals, 210 East 64th Street, 7th Floor, New York, NY 10065, United States.

E-mail addresses: tristan.klosterman@gmail.com, Tklosterman@alamedahealthsystem.org (T. Klosterman), hadarmen@yahoo.com (S. Ulkatan), dr.romo@romoplasticsurgery.com (T. Romo), teresaomd@gmail.com (O. Teresa).

<https://doi.org/10.1016/j.ijporl.2018.04.006>

Received 16 January 2018; Received in revised form 5 April 2018; Accepted 8 April 2018

Available online 12 April 2018

0165-5876/ © 2018 Elsevier B.V. All rights reserved.

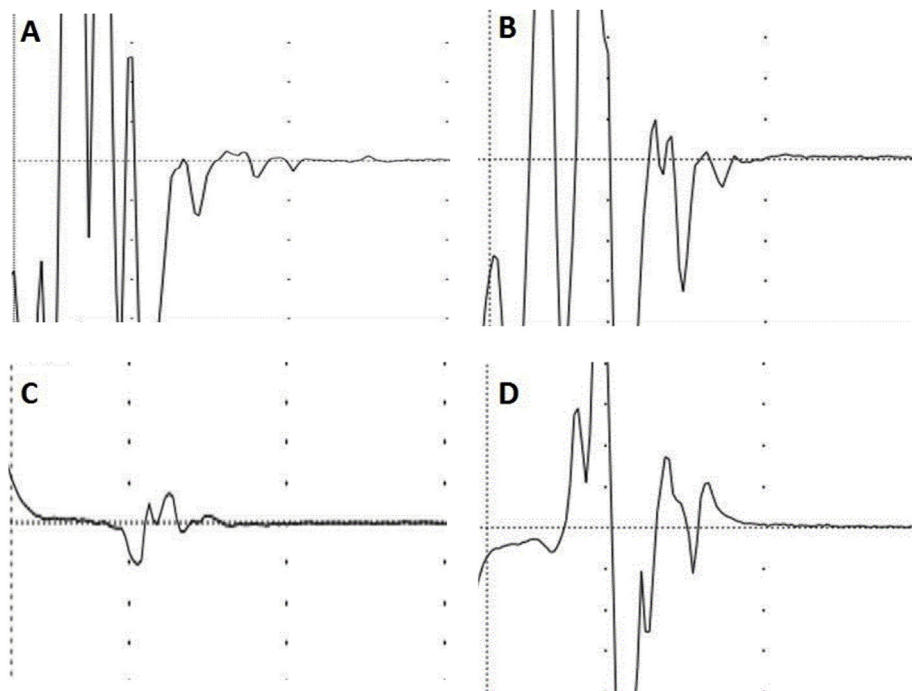


Fig. 1. Electrophysiological facial nerve recording of eight year old sister: (A) Right and (B) left marginal mandibular stimulation elicits normal mentalis muscle CMAP response. (C) Right cervical branch stimulation shows minimal platysma CMAP with no visible clinical contraction. (D) Left cervical branch stimulation shows a normal response.

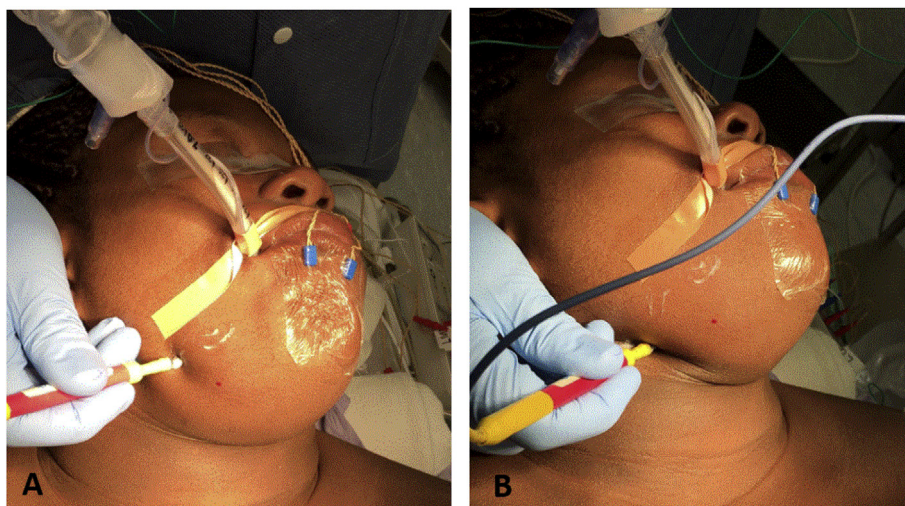


Fig. 2. Intraoperative photos of the older sibling on the paralyzed side showing dimpling with no downward pull upon stimulating the marginal mandibular branch (A) and absence of response to stimulating the cervical branch (B).

detect the action potential of the distal musculature when directly over the nerve. This allowed for a pen to be used to mark the positions of the cervical, marginal and buccal branches on the skin. Once mapped, a bipolar needle probe was placed near the stylomastoid foramen to stimulate the main facial nerve trunk and produce facial musculature tetany as needed through the case. Mapping was performed bilaterally.

The evaluation was performed on the younger sister first. Initial findings were unexpected upon nerve evaluation and revealed symmetric and intact bilateral marginal mandibular branch potentials (Fig. 1), while the right cervical branch was absent with no platysma stimulation. This was ascertained through additional bilateral platysma and cervical branch monitoring. After a thorough intraoperative discussion among the surgical and neuromonitoring staff, it was postulated that there was congenital lack of the cervical branch leading to absence of platysmal lower lip depression masquerading as marginal mandibular palsy. These findings were shared with the family and multiple options were discussed including no intervention, future

chemodenervation or surgical neurectomy. They elected to proceed with contralateral cervical branch neurectomy. A 2-cm incision was made in the cervical area over the cervical branch marking. The contralateral branches were identified and stimulation of the cervical branch revealed significant depression of the left lower lip. This branch was identified, doubly tied, and transected with removal of a 1cm intervening segment. Upon awakening, the patient was noted to have a symmetric smile.

The older sister was then brought to the operating room. Neuromonitoring results revealed the same absence of ipsilateral cervical branch function and thus only the contralateral cervical branch was sacrificed. Intraoperative video and photography were taken and illustrate the findings in the two sisters (Figs. 2–4). Postoperatively, both patients had symmetry at rest and with smile without functional deficit at one week and one month (Fig. 5). Further follow-up at one year showed a long-lasting result. Facial photography consent was obtained from the family for both patients.

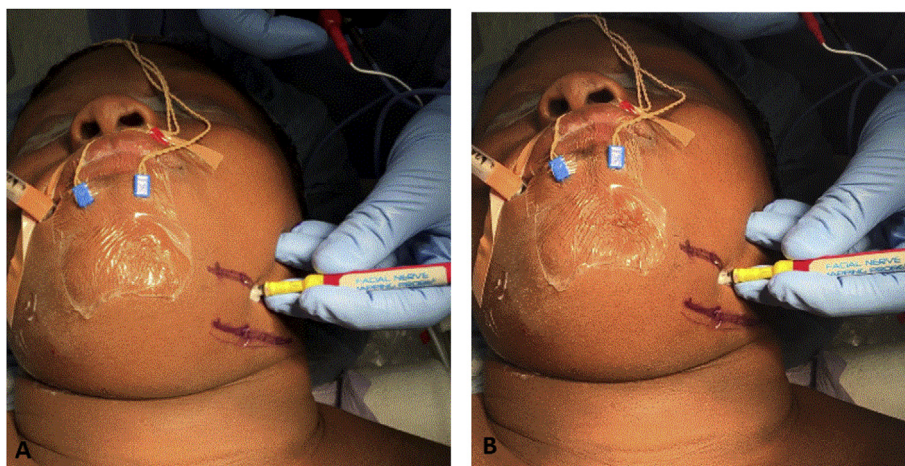


Fig. 3. Intraoperative photos of the older sibling on the nonparalyzed side showing the face at rest (A) and stimulation (B) of the marginal mandibular branch. Note the elevation of the oral commissure without depression of the lower lip.

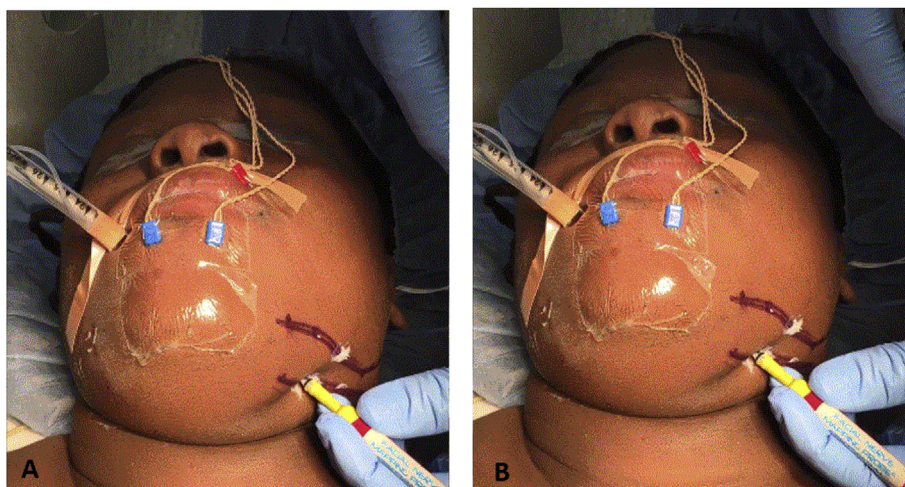


Fig. 4. Intraoperative photos of the older sibling on the nonparalyzed side showing the face at rest (A) and stimulation (B) of the cervical branch. Note the subtle widening and depression of the mid and lateral lower lip with stimulation.

3. Discussion

Familial facial nerve palsy is a rare entity that can result in significant clinical diagnostic and therapeutic challenges. These cases present manifestations that are unique to the literature. Unlike other reports, a unilateral branch palsy was seen without obvious inheritance pattern and no other family prevalence [1,2]. Congenital muscle hypoplasia was additionally not the overlying cause [3]. Our intraoperative findings were unexpected and required a revision of the surgical plan which highlights the difficulties in managing congenital palsies. Facial nerve monitoring and mapping allowed for precise identification and surgical modification, as contralateral marginal mandibular neurectomy would have been performed with a resulting deformity [4]. Furthermore, recent data suggest that there may be a significant variability in muscle innervation by individual facial nerve branches which further supports the value of electrophysiology monitoring [5].

Treatment options for asymmetric lower lip paralysis are varied and include static and dynamic approaches [1,6–8]. We chose selective neurectomy due to its targeted precision, ease of procedure, minimal incision, and reproducible results [9,10]. While chemodenervation with neuromuscular agents can be an excellent choice in many patients, the young age and desire for a single procedure did not allow for this approach [11]. Dynamic approaches have also been described, however,

the results are often less predictable [12]. As is common in facial nerve cases, one-size-fits all operations do not usually exist and individual patient wishes and concerns must be taken into account. This discussion is limited as only two patients are presented though the methods and procedures can be applicable in other facial palsies. A concern with any young patient is the long-term results in adulthood and beyond. Unfortunately, data is limited for outcomes greater than 24–36 months. Ptosis or asymmetry may present in the future but can be addressed with botox or minimally invasive cosmetic procedures [11,13–15].

Additionally, the cervical branch appeared to be absent on the affected side while the intact contralateral side contributed significantly to lower lip depression. While the platysma does exert some effect on the lower lip and face, its' contribution to the smile is not often thought to be significant [16]. Anatomical models often minimize the significance of this branch though recent authors do advocate sparing it to preserve facial symmetry [17]. During routine neck dissection patients may present with asymmetric smile despite preservation or avoidance of the marginal branch. As the cervical branch is often cut indiscriminately in these cases, there may be instances where platysmal contributions are underappreciated [17].

4. Conclusion

Familial facial nerve paralysis of isolated branches is a rare

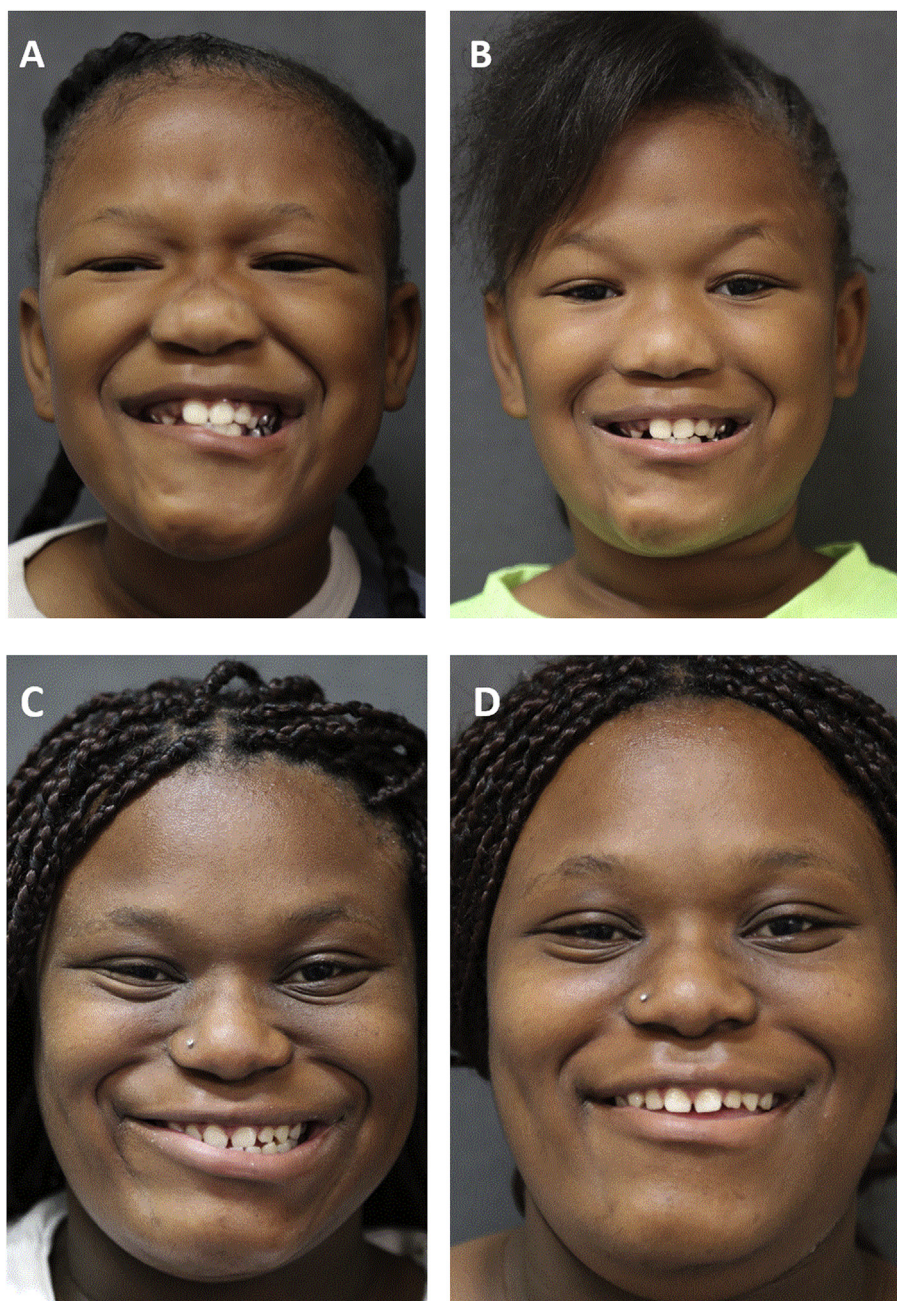


Fig. 5. Clinical photographs of the sisters revealing smile asymmetry preoperatively with significant resolution postoperatively after sacrifice of the contralateral cervical facial nerve branch. Eight year old sister pre (A) and post (B) operation. Fourteen year old pre (C) and post (D) operation.

phenomenon. To our knowledge, this is the first report of a familial cervical branch palsy resulting in significant facial asymmetry. It highlights the complexity of these cases and the importance of bilateral facial nerve monitoring and mapping when there is question of the etiology. Congenital palsies should be managed carefully as limited data is available to guide surgeons. Multiple therapeutic options including selective neurectomy and non-invasive options should be considered for these patients and tailored appropriately.

Disclosure

This research did not receive any specific grant from funding agencies in the public, commercial, or not-for-profit sectors.

References

- [1] A. Giorba, V. Corazzi, V. Conz, C. Bianchini, C. Aimoni, Facial nerve paralysis in children, *World J Clin Cases* 3 (12) (2015 Dec 16) 973–979.
- [2] I.S. Alrashdi, P. Rich, M.A. Patton, A family with hereditary congenital facial paresis and a brief review of the literature, *Clin. Dysmorphol.* 19 (4) (2010 Oct) 198–201.
- [3] S.O. Uluulp, R. Deskin, Congenital unilateral hypoplasia of depressor anguli oris, *Case Rep Pediatr* 2012 (2012) 507248. Epub 2012 Sep. 17.
- [4] S. Ulkatan, M. Waner, B. Arranz-Arranz, I. Weiss, T.M. O, M. Saral, V. Deletis, Berenstein. New methodology for facial nerve monitoring in extracranial surgeries of vascular malformations, *A. Clin Neurophysiol* 125 (4) (2014 Apr) 849–855.
- [5] A. Raslan, G.F. Volk, M. Möller, V. Stark, N. Eckhardt, O. Guntinas-Lichius, High variability of facial muscle innervation by facial nerve branches: a prospective electrostimulation study, *Laryngoscope* 127 (6) (2017 Jun) 1288–1295.
- [6] C.A. Banks, T.A. Hadlock, Pediatric facial nerve rehabilitation, *Facial Plast Surg Clin North Am.* 22 (4) (2014 Nov) 487–502.
- [7] G. Hussain, R.T. Manktelow, L.R. Tomat, Depressor labii inferioris resection: an effective treatment for marginal mandibular nerve paralysis, *Br. J. Plast. Surg.* 57 (6) (2004) 502–510.

- [8] J. Conley, D.C. Baker, R.W. Selfe, Paralysis of the mandibular branch of the facial nerve, *Plast. Reconstr. Surg.* 70 (5) (1982) 569–577.
- [9] G.D. Breslow, D. Cabiling, S. Kanchwala, S.P. Bartlett, Selective marginal mandibular neurectomy for treatment of the marginal mandibular lip deformity in patients with chronic unilateral facial palsies, *Plast. Reconstr. Surg.* 116 (5) (2005 Oct) 1223–1232.
- [10] M.H. Hohman, L.N. Lee, T.A. Hadlock, Two-step highly selective neurectomy for refractory periocular synkinesis, *Laryngoscope* 123 (6) (2013 Jun) 1385–1388.
- [11] S. Haykal, E. Arad, S. Bagher, C. Lai, M. Hohman, T. Hadlock, R.M. Zuker, G.H. Borschel, The role of botulinum toxin a in the establishment of symmetry in pediatric paralysis of the lower lip, *JAMA Facial Plast Surg* 17 (3) (2015 May-Jun) 174–178.
- [12] N. Jowett, R. Malka, T.A. Hadlock, Effect of weakening of ipsilateral depressor anguli oris on smile symmetry in postparalysis facial palsy, *JAMA Facial Plast Surg* 19 (1) (2017 Jan 1) 29–33.
- [13] J.S. Barr, K.A. Katz, A. Hazen, Surgical management of facial nerve paralysis in the pediatric population, *J. Pediatr. Surg.* 46 (11) (2011) 2168–2176.
- [14] M.C. Ferreira, Aesthetic considerations in facial reanimation, *Clin. Plast. Surg.* 29 (4) (2002) 523–532.
- [15] M.G. Glenn, R.L. Goode, Surgical treatment of the “marginal mandibular lip” deformity, *Otolaryngol. Head Neck Surg.* 97 (5) (1987) 462–468.
- [16] S.T. Tan, Anterior belly of digastric muscle transfer: a useful technique in head and neck surgery, *Head Neck* 24 (10) (2002 Oct) 947–954.
- [17] C.A. Righini, J. Petrossi, E. Reyt, I. Atallah, An original submandibular approach technique sparing the cervical branch of the facial nerve, *Eur Ann Otorhinolaryngol Head Neck Dis* 131 (2) (2014 Apr) 143–146.